Current Rheumatology Reports (2020) 22:53
https://doi.org/10.1007/s11926-020-00930-7

SPONDYLOARTHRITIS (M KHAN, SECTION EDITOR)

Hip and Shoulder Involvement and Their Management in Axial Spondyloarthritis: a Current Review

Clementina López-Medina [1,2,3,4] · M. Carmen Castro-Villegas [1,2,3] · Eduardo Collantes-Estévez [1,2,3]

Abstract

Purpose of Review Hip and shoulder disease can occur in patients with spondyloarthritis (SpA). While hip involvement has been widely assessed in axial SpA patients, studies in the overall SpA population as well as studies focused on shoulder involvement are scarce. Here, we review the most recent studies on the epidemiology, evaluation, and treatment of root joint involvement in SpA patients.

Recent Findings Radiological hip involvement can affect up to 25% of patients with SpA, reflecting more severe disease and associated with functional impairment. Shoulder involvement in SpA patients is characterized by cuff tendinitis and enthesitis, while primary glenohumeral joint involvement is rare. Anti-tumor necrosis factor (anti-TNF) treatment in SpA patients seems to have an effect on hip arthritis, showing a change in trend in the frequency of hip replacement in this population.

Summary The majority of studies evaluating hip involvement have focused on axial SpA patients, but further studies evaluating root joint involvement in the overall SpA population are needed. Anti-TNF therapy should be considered in patients with hip involvement, and root joint involvement should be assessed routinely in clinical practice.

Keywords Spondyloarthritis · Hip · Shoulder · Epidemiology · Imaging · Outcomes

Introduction

Spondyloarthritis (SpA) is a group of inflammatory rheumatic disorders that mainly affect the axial skeleton and sacroiliac joints. Classically, SpA has been classified into several subtypes, such as ankylosing spondylitis (AS), psoriatic arthritis (PsA), inflammatory bowel disease (IBD)-associated SpA, reactive arthritis (ReA) and undifferentiated SpA (u-SpA) [1]. In 2011, the Assessment of Spondyloarthritis International Society (ASAS) developed a new set of criteria and introduced the concept of axial SpA (axSpA) (AS is the prototype of axSpA) and peripheral SpA (pSpA), depending on the presence of predominantly axial or predominantly peripheral involvement, respectively [2]. Arthritis is the most common peripheral feature in SpA and is commonly located in the lower limbs [3]. Peripheral joint involvement is more frequent among patients with pSpA [4]; however, root joint involvement, such as hip involvement, has been described as being associated with axSpA, while data for shoulder involvement are scarce.

In this review, we provide an update on the epidemiology, evaluation, impact, and management of root joint involvement (hip and shoulder) in patients with axSpA.

Pathophysiology of Peripheral Articular Involvement in Spondyloarthritis

The inflammation of the enthesis (tendon insertion sites into bone) represents the hallmark pathophysiological feature in

This article is part of the Topical Collection on *Spondyloarthritis*

✉ Eduardo Collantes-Estévez
educollantes@yahoo.es

Clementina López-Medina
clementinalopezmedina@gmail.com

M. Carmen Castro-Villegas
mcasvi@yahoo.es

1 Rheumatology Department, Reina Sofia University Hospital, Avda. Menéndez Pidal s/n, Cordoba, Spain

2 Maimonides Institute of Biomedical Research of Cordoba (IMIBIC), Cordoba, Spain

3 Medicine Department, University of Cordoba, Cordoba, Spain

4 Rheumatology Department, Cochin Hospital, Paris, France

Published online: 23 July 2020

SpA and triggers the local tissue response [5••]. In SpA patients, synovitis and joint effusion are caused by the intrinsic dysregulation of the enthesis, with the liberation of pro-inflammatory mediators driving adjacent soft tissue inflammation; thus, enthesitis seems to be the cardinal lesion, while synovitis and osteitis may occur thereafter [6••].

Hip involvement is a feature of SpA that is caused by the inflammation of the coxofemoral joint and is defined as an excess of inflammatory synovial fluid and/or cartilage destruction [7]. Histological data from biopsies suggest two processes: inflammation and new bone formation. Inflammation in bone cartilage seems to be driven by increased vascularity, high percentage of CD68+ cells, and high expression of matrix metalloproteinases-3 (MMP-3) in comparison with patients with osteoarthritis (OA) [8].

Shoulder lesions in axSpA are characterized by cuff tendinitis and enthesitis localized at the supraspinatus/greater tuberosity and deltoid/acromial entheses. Moreover, lesions in the acromioclavicular joint are very frequent and acromial bone edema at the deltoid origin has been described as a specific feature of axSpA [9]. Unlike hip involvement, primary glenohumeral joint involvement of the shoulder is not a feature of SpA patients [9].

Epidemiology of Hip and Shoulder Involvement

The overall prevalence of hip involvement among SpA patients varies depending on the different definitions and on the population being investigated. The majority of studies evaluating hip involvement are focused on AS, the prototype of axSpA. Among this population, clinical hip impairment, defined on the basis of the rheumatologist's clinical perception during physical exploration, ranges between 24 and 36% [10, 11]. However, considering only patients with radiological findings, these percentages decreased to 9 to 22% [11, 12]. One study including all types of SpA (not only axSpA) reported a prevalence of radiological hip involvement of 18%, with a higher prevalence as disease duration increased (e.g., up to 25% after a duration of disease of 20 years) [7]. This high prevalence among patients with a long disease duration and, therefore, among older patients makes it important to correctly differentiate between primary inflammatory and secondary degenerative hip involvement. However, it has been shown that if hip involvement had not occurred in the first 10 years of the disease, it was highly unlikely to occur later [13, 14].

It is consistent in all studies that early age at disease onset of SpA is associated with hip involvement [7, 10, 14]. Patients with juvenile onset (i.e., age at disease onset less than 16 years) of axSpA are at the highest risk of developing hip disease and the subsequent need for hip replacement [10].

The fact that hip involvement can be found more frequently among patients with more severe axial disease (such as more radiological severity in the spine and more limited cervical rotation and lumbar flexion) led Amor et al. to consider hip involvement as a severity criterion of SpA disease [15]. Moreover, these findings gave rise to the hypothesis that hips, together with the shoulders, can be considered "root joints," which behave more similarly to the spine than to other peripheral joints [11, 16]. However, despite this relationship between hip impairment and axial disease, no study has demonstrated an association between hip involvement and HLA-B27 status. Interestingly, the only study that analyzed the overall SpA population found that radiographic hip findings were not associated with inflammatory back pain or with radiographic sacroiliítis [7]. This demonstrates the need to study root joints in the overall SpA population.

Data concerning shoulder involvement in SpA patients are very limited. The reported prevalence based on clinical assessment ranges from 7 to 33%, with an increased prevalence among patients with long-standing axSpA [17–19]. Patients with disabling shoulder pain have greater involvement of the hip and knee. Similar to the hip, shoulder involvement is also associated with worse spinal mobility, and no association has been found with HLA-B27 status [18]. However, because shoulder involvement has also been evaluated only in patients with axSpA, these results should be interpreted with caution.

Assessment of Hip Involvement

Clinical

Several anatomical structures in the coxofemoral joint can be involved in the inflammatory process, such as synovitis, enthesitis, bursitis, and bone marrow edema [20••]. The clinical pattern of coxofemoral disease includes inguinal pain impairment and painful movement of the hip [21]. There are basic tests that need to be conducted when examining a painful hip: skin inspection, neurovascular assessment, palpation, the range of movement (ROM) test and strength assessment [22]. The most important test to determine both osseous and ligamentous functions is the ROM test. Internal and external rotation ROM tests are performed passively in a supine position with the hip flexed 90°, and the ROM is dictated by a firm endpoint or by patient pain [22]. The straight leg raise against resistance test is an assessment of hip/flexor psoas strength and can indicate an interarticular problem as the psoas places pressure on the labrum in active resistance. The patient performs an active straight leg raise to 45°, while the examiner's hand is placed proximal to the knee applying downward force. A positive test is dictated by re-creation of the patient's pain or weakness [22]. Finally, palpation is usually used to assess potential sources of pain other than the joint itself.

Palpations of the lumbar spine, sacroiliac joints, ischium, iliac crests, treater trochanter, trochanter bursa, and pubic symphysis should be systematically evaluated [23].

For the quantification of hip involvement in SpA patients, some tests have been developed. The intermalleolar distance (IMD) is one of the items included in the Bath Ankylosing Spondylitis Metrology Index (BASMI) [24]. In this test, the subject lies down with the legs separated as far as possible with the knees straight. The distance between the medial malleoli is measured to the nearest centimeter [25]. However, because many patients found IMD uncomfortable, the internal rotation of the hip (IHR) measurement was developed, which is part of the Edmonton Ankylosing Spondylitis Metrology Index (EDASMI) [26]. In this IHR test, the subject is seated on the examining table with knees and hips flexed 90° and knees together, clasping a piece of card paper between the knees. The subject is asked to move the ankles apart as far as possible without releasing the card paper from between the knees. The distance between the medial malleoli is recorded in centimeters. However, it has been demonstrated that the correlation between the IMD and the IHR is weak; therefore, these two tests are not interchangeable [25].

Imaging

X-Ray

Unlike the classic changes of axSpA in the spine, synovial inflammation within the hip joint does not cause new bone formation but presents with bone erosion and joint space narrowing, which can be assessed by conventional X-ray images [12]. The most frequent finding is the concentric joint space narrowing, with axial migration of the femoral head and osteophytosis, which sometimes progresses to collar osteophytes around the femoral neck (Fig. 1). It is not uncommon to see acetabular protrusion and subchondral cysts. Hip ankylosis is rare, and it can appear as a consequence of the ossification of the capsule. The pubic symphysis can be seen in the same projection of the hip, and it can manifest erosions, sclerosis, and ankylosing (Fig. 2) [27].

The most widely used index to evaluate the severity of hip involvement in patients with SpA is the Bath Ankylosing Spondylitis Radiology Index (BASRI) [28]. The total BASRI score includes the BASRI-hip (range 0–4) and the BASRI-spine (range 2–12), which combines the scores of the sacroiliac joints, lumbar spine, and cervical spine. In the BASRI-hip score, the hips are graded as follows: 0 = normal (no change), 1 = suspicious (possible focal joint space narrowing), 2 = minimal (definite narrowing, leaving a circumferential joint space >2 mm), 3 = moderate (narrowing but with circumferential joint space ≤ 2 mm or bone-on-bone apposition of < 2 cm), and 4 = severe disease (bone deformity or bone-on-bone apposition > 2 cm or total hip replacement).

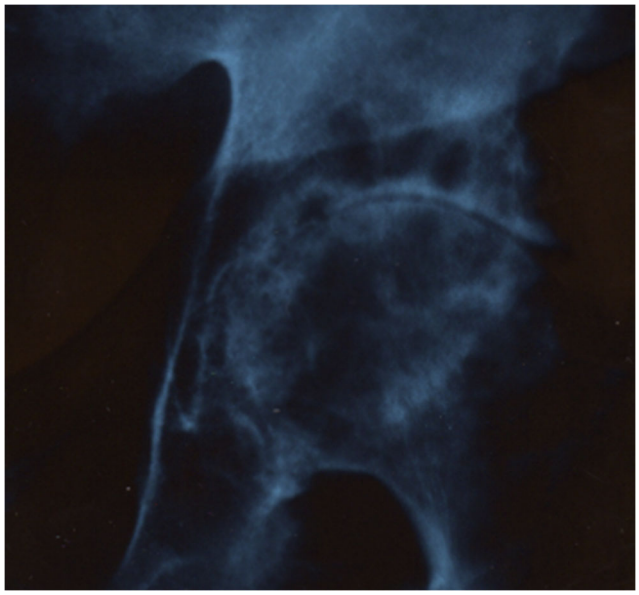

Fig. 1 X-ray image of left hip of 54-year-old male with axial spondyloarthritis. Typical radiographic features of hip involvement in a patient with axial SpA: global space narrowing, collar osteophytes around the femoral neck, erosions, and subchondral cysts

Magnetic Resonance Imaging

Magnetic resonance image (MRI) of the hip allows the detection of the initial onset of hip involvement. In a recent study conducted in 186 patients with AS and pain or limited function of the hips, synovial enhancement was the most frequent imaging finding, which was reflected by hyperintense signals on contrast-enhanced T1-weighted fat-saturated images in the synovial portion of the hip joint [29•]. Joint effusion has also been described as a frequent MRI finding, considered when

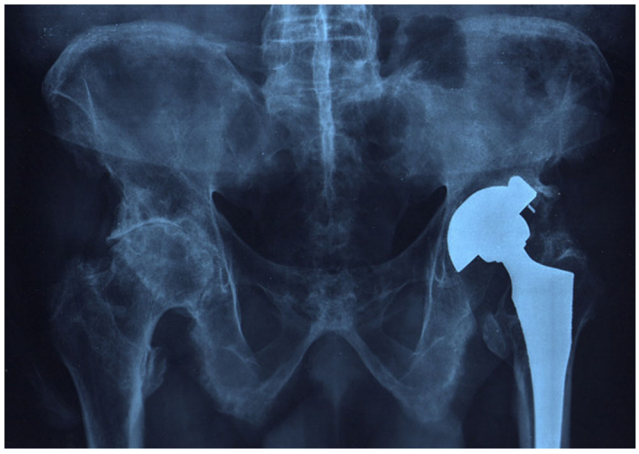

Fig. 2 X-ray image of pelvis of 54-year-old male with axial Spondyloarthritis. Right hip: global space narrowing, collar osteophytes around the femoral neck and erosions. Left hip: total hip replacement. Sclerosis and ankylosis of the pubic symphysis

fluid surrounds the femoral neck or when a distended joint capsule on T_2WI or STIR images exists [30]. Subchondral bone marrow edema is also a frequent finding, and it is defined as a hyperintense signal on STIR images and/or on contrast-enhanced T1-weighted fat-saturated images located in the subchondral or periarticular bone marrow. Finally, enthesitis is defined as a hyperintense signal on STIR images and/or on contrast-enhanced T1-weighted fat-saturated images at sites where ligaments and tendons attached to bone [30].

Ultrasound

Hip ultrasound (US) has become a very useful imaging tool for hip evaluation due to its accessibility, availability, lack of radiation exposure, and low cost. US can be of supplementary value to distinguish symptoms related to inflammatory or degenerative hip lesions. Hip joints must be assessed bilaterally in two orthogonal planes. The most important abnormalities that should be assessed are effusion, erosions, osteophytes, calcifications, and vascularization [20••]. Effusion is observed as a hypoechoic fluid collection that distends the capsule. Joint effusion is diagnosed when the distance between the anterior layer of the synovium and the femoral neck is greater than 7 mm or when the difference between both hips is greater than 1 mm [31, 32]. The vascularity of the synovial membrane of the hip can be assessed using the color power Doppler technique, allowing the detection of early inflammation of synovial tissue [33]. Finally, the combination of osteophytes and erosions/irregular cortex is usually considered osteoarthritis/degenerative changes [20••].

Assessment of Shoulder Involvement

Clinical

A limitation of the mobility of the scapulothoracic unit is the most frequent clinical finding. In most cases it is bilateral and symmetrical, leading to a loss of antepulsion and, to a lesser degree, shoulder abduction. Unilateral inflammation of the acromioclavicular joint can also be observed [34].

Inspection, palpation, range of motion assessment, and special tests for the shoulder should be conducted [35]. The acromioclavicular joint should be carefully palpated since the inflammation of this joint is very frequent among SpA patients. The range of motion should be assessed actively and passively.

Because rotator cuff tendinitis is a very prevalent finding among SpA patients, this should be systematically evaluated in these patients. Rotator cuff tendons include the supraspinatus (which assists in the abduction of the arm), infraspinatus, teres minor (both of them implicated in external rotation), and subscapularis (implicated in internal rotation), while the long head of the biceps tendon is also often included in rotator cuff pathology [36]. Passive motion is typically limited in glenohumeral articular disorders, while a loss of active range of motion is usually caused by rotator cuff tears. One of the most sensitive and specific tests for the examination of the rotator cuff is Hornblower's sign: the patient is asked to bring the hands to the mouth. If the rotator is affected, the patient can reach the mouth but only with the elbow in a high position and the wrist in extension; if the rotator is intact, the patient can reach the mouth without bringing the elbow high [37].

Imaging

X-Ray

Two types of radiographic shoulder involvement in SpA have been described: the nondestructive and destructive forms. The nondestructive form is characterized by a humeral head ankylosed to the glenoid and the ossification of the coracoclavicular ligament. On the other hand, the destructive form is described as an erosion of the humeral head due to an enthesitis, which becomes hatchet-shaped, the "hatchet" sign [38, 39]. Although the acromioclavicular joint is the most common site of shoulder involvement in SpA, radiographic changes in this location are mostly degenerative. Rotator cuff rupture or atrophy may also lead to superior migration of the humeral head [40].

Magnetic Resonance Imaging

It has been described that many asymptomatic patients have MRI abnormalities due to shoulder inflammation [9, 40]. Intense entheseal bone marrow edema (BME), particularly in the acromion and in association with erosion at the greater tuberosity, has been described as the most specific finding in AS shoulders (Fig. 3) [9]. Another frequent finding is the entheseal BME in the adhesion locations of the deltoid and supraspinatus tendon [40].

Ultrasound

US has proven to be a reliable method for assessing tendons and entheses in SpA. The most frequent finding in US evaluation of shoulders in patients with SpA is multiple entheseal involvement, especially supraspinatus insertion [41, 42]. Enthesitis can be observed as tendon thickening at the level of bony attachment, bony erosion, enthesophytes, and Doppler signal [41]. Rotator cuff tendinopathy is also frequent, characterized by partial- or full-thickness tears and intratendinous calcifications. Glenohumeral synovitis is an uncommon finding in these patients [41].

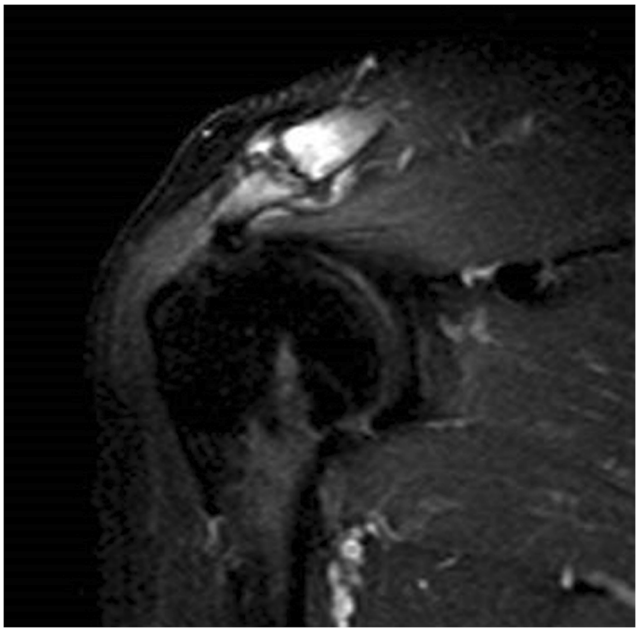

Fig. 3 Magnetic resonance image of right shoulder of 44-year-old female with axial Spondyloarthritis. Abnormal bright signal is seen in and around the acromioclavicular joint with bone marrow edema, suggestive of acromioclavicular arthritis

Impact of Hip and Shoulder Involvement

Root joint involvement has a great impact on patient function and mobility. It has been reported that patients with hip involvement (clinical or radiological) have a worse Bath Ankylosing Spondylitis Function Index (BASFI) [43] than those without hip involvement. Moreover, BASFI items that are not directly related to the hip have been described as being worse in these patients. One possible explanation is that the patient's judgment of functional impairment not only reflects the range of motion in the hip but also hampers other activities related to spinal mobility [10]. In fact, poorer mobility assessed with the BASMI is also associated with hip and shoulder involvement [12, 19]. One recent study in axSpA patients suggested that hip involvement has a more prominent role than axial structural damage in functional limitations in these patients and that hip arthritis may also influence the ability to compensate for an inflexible lumbar spine, exaggerating functional limitations [44•]. Function and mobility restrictions due to hip and shoulder involvement may lead to detriment to the quality of life, causing work loss and sick leave [10].

Root joint involvement also has an impact on treatment intake. It has been described that SpA patients with hip arthritis use anti-TNF drugs more frequently than patients without hip arthritis [12]. This was later confirmed in a French study, in which patients with hip involvement were more often treated with anti-TNF medications for the management of symptoms, confirming hip involvement as a marker of severity in these patients [7]. Interestingly, no differences have been described in nonsteroidal anti-inflammatory drugs (NSAIDs) and disease-modifying drug intake between patients with and without shoulder involvement [19].

Management of Hip and Shoulder Involvement

Pharmacological Treatment

Studies of therapy in SpA are mainly focused on the spine and on radiographic progression in the axial skeleton and, to a lesser extent, on peripheral arthritis or enthesitis. However, no randomized clinical trial has been conducted on hip involvement, and the only published data correspond to observational studies. Lian F et al. suggested that etanercept therapy in combination with methotrexate in Chinese patients with AS hip joint lesions was effective after 3 months of follow-up as assessed by the BASDAI and BASFI [45]. Later, a study conducted in Greece in 23 patients with AS and radiographic hip involvement treated with infliximab for 6 years found that the average width of the whole joint space was not reduced, suggesting that radiographic progression of hip arthritis in these patients may be arrested during infliximab treatment [46]. In 2017, Song R et al. demonstrated in six patients treated with anti-TNFalpha (either infliximab, adalimumab, or etanercept) not only an arrested progression but also increased hip joint space width increased in all patients [47•]. Anti-TNFalpha treatment also seemed to have effects on lesions viewed by US. A large study conducted in 85 AS patients starting with anti-TNF alpha therapy found a significant decrease in the total number of inflammatory lesions and positive power Doppler signal at the hip joints after 6 months of therapy [20••]. Finally, a change in trend in the frequency of hip replacement procedures in patients with AS has been observed in the Norwegian population in recent years, suggesting a reduced incidence and/or severity of large-joint arthritis, which coincides with the initiation of anti-TNF alpha treatment in this population [48]. This lack of studies highlights the need to conduct randomized studies focused on the treatment effect of treatment on root joints in SpA patients.

An alternative therapeutic option to systemic treatment of the hip is local intraarticular infiltration of corticoids. However, despite its rapid effect on pain, it remains unclear whether this can prevent long-term coxofemoral damage [11].

Physical Therapy

Physical therapy in SpA patients is important to maintain mobility and flexibility and to prevent joint deformity, especially in the spine. Three types of physical therapy for SpA patients exist: supervised individualized therapy, unsupervised self-

administered individualized therapy, and supervised group therapy [49]. Supervised home-based daily exercise therapy has been demonstrated to be effective on joint mobility, functional capacity, pain, and depression in patients with axSpA. Thirty minutes including hip flexor-quadriceps stretches, hip extensor exercises, and alternating hip extensor exercises and shoulder circles demonstrated a significant improvement in shoulder flexion and horizontal abduction, as well as in hip abduction [50]. Interestingly, group physical therapy has been proven to have a superior effect on global health in comparison with individualized therapy [49].

Replacement Surgery

Total hip replacement (THR) is an effective treatment for chronic hip arthritis in patients with axSpA. After 30 years of axSpA, between 12 and 25% of patients will need THR [9]. In a recent study conducted in the UK that included 9766 patients with axSpA, a total of 173 THRs occurred, with an incidence rate of 2.65/1000 patient-years. Moreover, the overall 5-year cumulative percentage probability of THR was 1.28% (95% CI 1.05–1.55) [51]. Classic factors independently associated with hip replacement are disease duration, entheseal disease, age at onset less than 16, and severe axial radiology [10]. Recently, it has been described that THR rates rose with increasing age, but there was no association with age, geographic region or availability of anti-TNF treatment [51].

In 2016, the American College of Rheumatology (ACR) and the European League Against Rheumatism (EULAR) provided guidance for practice in axSpA patients [52,53••]. They strongly recommended treatment with THR in patients with radiographic evidence of hip damage and severe hip pain who experience progressive limitations in mobility or in quality of life, independent of age. The rationale for this recommendation is the results of observational studies that demonstrated postoperative improvements in pain, functioning, and hip range of motion [52]. Perioperative complications, 30-day complications and local infections are rare after primary THR in patients with axSpA and similar in frequency to those without axSpA [44•].

Conclusion

Hip involvement can affect up to 25% of patients with SpA, reflecting a more severe disease and associated with functional impairment. The majority of studies evaluating hip involvement have focused on axSpA patients, but further studies evaluating root joints involvement in the overall SpA population are needed. Shoulder involvement in SpA patients is characterized by cuff tendinitis and enthesitis, while primary glenohumeral joint involvement of the shoulder is rare. Anti-TNFalpha treatment in SpA patients seems to have an effect on hip arthritis, showing a change in trend in the frequency of hip replacement in this population. Root joint involvement should be assessed routinely in clinical practice.

Acknowledgments M. Carmen Castro-Villegas passed away during the preparation of this manuscript. All her friends and patients would like to thank M. Carmen for her dedication to and love for rheumatology, especially for spondyloarthritis.

Compliance with Ethical Standards

Conflict of Interest The authors declare that they have no conflict of interest.

Human and Animal Rights and Informed Consent This article does not contain any studies with human or animal subjects performed by any of the authors.

References

Papers of particular interest, published recently, have been highlighted as:
• Of importance
•• Of major importance

1. Dougados M, Baeten D. Spondyloarthritis. Lancet. 2011;377: 2127–37. https://doi.org/10.1016/S0140-6736(11)60071-8.
2. Rudwaleit M, van der Heijde D, Landewé R, et al. The assessment of spondyloarthritis international society classification criteria for peripheral spondyloarthritis and for spondyloarthritis in general. Ann Rheum Dis. 2011;70:25–31. https://doi.org/10.1136/ard.2010.133645.
3. Sieper J, Poddubnyy D. Axial spondyloarthritis. Lancet. 2017;390: 73–84. https://doi.org/10.1016/S0140-6736(16)31591-4.
4. Del Rio-Martinez P, Navarro-Compán V, Díaz-Miguel C, Almodóvar R, Mulero J, De Miguel E, et al. Similarities and differences between patients fulfilling axial and peripheral ASAS criteria for spondyloarthritis: results from the Esperanza cohort. Semin Arthritis Rheum. 2016;45:400–3. https://doi.org/10.1016/j.semarthrit.2015.09.001.
5.•• Schett G, Lories RJ, D'Agostino MA, Elewaut D, Kirkham B, Soriano ER, et al. Enthesitis: from pathophysiology to treatment. Nat Rev Rheumatol. 2017;13:731–41. https://doi.org/10.1038/nrrheum.2017.188. **This review provides an insight into the pathophysiology of enthesitis, addressing the role of biomechanics, prostaglandin E2-mediated vasodilation, and the activation of innate immune cells in the initiation phase of enthesitis**.
6.•• Bridgewood C, Sharif K, Sherlock J, Watad A, McGonagle D. Interleukin-23 pathway at the enthesis: the emerging story of enthesitis in spondyloarthropathy. Immunol Rev. 2020;294:27–47. https://doi.org/10.1111/imr.12840. **In SpA disorders target the tendon, ligament, and joint capsule skeletal anchorage points that are termed entheses**.
7. Burki V, Gossec L, Payet J, Durnez A, Elhai M, Fabreguet I, et al. Prevalence and characteristics of hip involvement in spondyloarthritis: a single-centre observational study of 275 patients. Clin Exp Rheumatol. 2012;30:481–6.

8. Chen WS, Chen CH, Lin KC, Tsai CY, Liao HT, Wang HB, et al. Immunohistological features of hip synovitis in ankylosing spondylitis with advanced hip involvement. Scand J Rheumatol. 2009;38:154–8. https://doi.org/10.1080/03009740802409504.
9. Lambert RGW, Dhillon SS, Jhangri GS, Sacks J, Sacks H, Wong B, et al. High prevalence of symptomatic enthesopathy of the shoulder in ankylosing spondylitis: deltoid origin involvement constitutes a hallmark of disease. Arthritis Rheum. 2004;51:681–90. https://doi.org/10.1002/art.20681.
10. Vander Cruyssen B, Muñoz-Gomariz E, Font P, Mulero J, de Vlam K, Boonen A, et al. Hip involvement in ankylosing spondylitis: epidemiology and risk factors associated with hip replacement surgery. Rheumatology (Oxford). 2010;49:73–81. https://doi.org/10.1093/rheumatology/kep174.
11. Vander Cruyssen B, Vastesaeger N, Collantes-Estevez E. Hip disease in ankylosing spondylitis. Curr Opin Rheumatol. 2013;25:448–54. https://doi.org/10.1097/BOR.0b013e3283620e04.
12. Chen HA, Chen CH, Liao HT, Lin YJ, Chen PC, Chen WS, et al. Factors associated with radiographic spinal involvement and hip involvement in ankylosing spondylitis. Semin Arthritis Rheum. 2011;40:552–8. https://doi.org/10.1016/j.semarthrit.2010.07.008.
13. Zhao J, Zheng W, Zhang C, Li J, Liu D, Xu W. Radiographic hip involvement in ankylosing spondylitis: factors associated with severe hip diseases. J Rheumatol. 2015;42:106–10. https://doi.org/10.3899/jrheum.140428.
14. Khan MA, van der Linden S. Ankylosing spondylitis and other Spondyloarthropathies. Rheum Dis Clin N Am. 1990;16(3):551–79.
15. Amor B, Santos RS, Nahal R, Listrat V, Dougados M. Predictive factors for the longterm outcome of spondyloarthropathies. J Rheumatol. 1994;21:1883–7.
16. Calin A, Elswood J. The relationship between pelvic, spinal and hip involvement in ankylosing spondylitis: one disease process or several? Br J Rheumatol. 1988;27:393–5. https://doi.org/10.1093/rheumatology/27.5.393.
17. Emery RJ, Ho EK, Leong JC. The shoulder girdle in ankylosing spondylitis. J Bone Joint Surg Am. 1991;73:1526–31.
18. Will R, Kennedy G, Elswood J, Edmunds L, Wachjudi R, Evison G, et al. Ankylosing spondylitis and shoulder: commonly involved but infrequently disabling. J Rheumatol. 2000;27:177–82.
19. Eksioglu E, Bal A, Gulec B, Aydog E, Cakci A. Assessment of shoulder involvement and disability in patients with andkylosing spondylitis. Rheumatol Int. 2006;27:169–73. https://doi.org/10.1007/s00296-006-0182-8.
20.•• Wink F, Arends S, Maas F, Bootsma H, Griep EN, Bruyn GAW, et al. High prevalence of hip involvement and decrease in inflammatory ultrasound lesions during tumour necrosis factor-α blocking therapy in ankylosing spondylitis. Rheumatology (Oxford). 2019;58:1040–6. https://doi.org/10.1093/rheumatology/key382. **Highest concordance was found between history of hip involvement and radiographic hip involvement. Ultrasound is useful for the evaluation of anatomical structures on the hip. TNF-α blocking therapy significantly improved tender hip joints, and inflammatory ultrasound lesions including positive power Doppler**.
21. Cibulka MT, White DM, Woehrle J, Harris-Hayes M, Enseki K, Fagerson TL, et al. Hip pain and mobility deficits—hip osteoarthritis: clinical practice guidelines linked to the international classification of functioning, disability, and health from the orthopaedic section of the American Physical Therapy Association. J Orthop Sports Phys Ther. 2009;39:A1–25 https://www.jospt.org/doi/10.2519/jospt.2009.0301.
22. Martin HD, Kelly BT, Leunig M, Philippon MJ, Clohisy JC, Martin RL, et al. The pattern and technique in the clinical evaluation of the adult hip: the common physical examination tests of hip specialists. Arthroscopy. 2010;26:161–72. https://doi.org/10.1016/j.arthro.2009.07.015.
23. Byrd JW. Evaluation of the hip: history and physical examination. N Am J Sports Phys Ther. 2007;2:231–40.
24. Jenkinson TR, Mallorie PA, Whitelock HC, Kennedy LG, Garrett SL, Calin A. Defining spinal mobility in ankylosing spondylitis (AS): the Bath AS Metrology Index. J Rheumatol. 1994;21:1694–8.
25. Stolwijk C, Ramiro S, Vosse D, Landewé R, van der Heijde D, van Tubergen A. Comparison of tests for lumbar flexion and hip function in patients with and without axial spondyloarthritis. Arthritis Care Res. 2015;67:538–45. https://doi.org/10.1002/acr.22464.
26. Maksymowych WP, Mallon C, Richardson R, Conner-Spady B, Jauregui E, Chung C, et al. Development and validation of the Edmonton Ankylosing Spondylitis Metrology Index. Arthritis Rheum. 2006;55:575–82. https://doi.org/10.1002/art.22103.
27. Sanz Sanz J, Mulero MJ. Radiología y otras técnicas de imagen en espondilitis anquilosante. In: Sanmarti R, editor. Monografías SER. Espondiloartritis. Madrid: Panamericana; 2004. p. 114–5. ISBN 84-7903-905-1.
28. Mackay K, Brophy S, Mack C, Doran M, Calin A. The development and validation of a radiographic grading system for the hip in ankylosing spondylitis: the Bath Ankylosing Spondylitis Radiology Hip Index. J Rheumatol. 2000;27:2866–72.
29.• Chen D, Yuan S, Zhan Z, Xiao Y, Hao L, Liang L, et al. Early-stage hip involvement in patients with ankylosing spondylitis: a Chinese study based on magnetic resonance imaging. Mod Rheumatol. 2016;26:933–9. https://doi.org/10.3109/14397595.2016.1153232. **MRI was superior to radiography for the detection of early-stage hip involvement**.
30. Zhen-Guo H, Xue-Zhe Z, Wen H, Guo-Chun W, Hui-Quiong Z, Xin L, et al. The application of MR imaging in the detection of hip involvement in patients with ankylosing spondylitis. Eur J Radiol. 2013;82:1487–93. https://doi.org/10.1016/J.EJRAD.2013.03.020.
31. Koski JM, Antilla PJ, Isomaki HA. Ultrasonography of the adult hip joint. Scand J Rheumatol. 1989;18:113–7. https://doi.org/10.3109/03009748909099926.
32. Lin YT, Wang TG. Ultrasonographic examination of the adult hip. J Med Ultrason. 2012;20:201–9. https://doi.org/10.1016/j.jmu.2012.10.009.
33. Walther M, Harms H, Krenn V, Radke S, Kirschner S, Gohlke F. Synovial tissue of the hip at power doppler US: correlation between vascularity and power doppler US signal. Radiology. 2002;225:225–31. https://doi.org/10.1148/radiol.2251011272.
34. Eduardo CQ. Manifestaciones Clinicas articulares en espondilitis anquilosante. In: Sanmarti R, editor. Monografías SER. Espondiloartritis. Madrid: Panamericana; 2004. p. 85. ISBN 84-7903-905-1.
35. Donnelly TD, Ashwin S, Macfarlane RJ, Waseem M. Clinical assessment of the shoulder. Open Orthop J. 2013;7:310–5. https://doi.org/10.2174/1874325001307010310.
36. Jain NB, Wilcox RB, Katz JN, Higgins LD. Clinical examination of the rotator cuff. PM R. 2013;5:45–56. https://doi.org/10.1016/j.pmrj.2012.08.019.
37. Walch G, Boulahia A, Calderone S, Robinson AH. The "dropping" and "hornblower's" signs in evaluation of rotator-cuff tears. J Bone Joint Surg (Br). 1998;80:624–8. https://doi.org/10.1302/0301-620x.80b4.8651.
38. Horta-Baas G, Jiménez-Balderas FJ. Radiographic findings of shoulder involvement in ankylosing spondylitis. Rheumatol Clin. 2016;12:296–7. https://doi.org/10.1016/j.reuma.2015.11.003.
39. Sankaye P, Ostlere S. Arthritis at the shoulder joint. Semin Musculoskelet Radiol. 2015;19:307–18. https://doi.org/10.1055/s-0035-1549324.
40. Soker G, Bozkirli ED, Soker E, Gulek B, Arslan M, Memis D, et al. Magnetic resonance imaging evaluation of shoulder joint in patients

with early stage of ankylosing spondylitis: a case-control study. Diagn Interv Imaging. 2016;97:419–24. https://doi.org/10.1016/j.diii.2015.10.003.

41. Ali Ou Alla S, Bahiri R, Amine H, El Alaoui H, Rkain H, Aktaou S, et al. Ultrasound features of shoulder involvement in patients with ankylosing spondylitis: a case-control study. BMC Musculoskelet Disord. 2013;14:272. https://doi.org/10.1186/1471-2474-14-272.
42. Riente L, Delle Sedie A, Filippucci E, Iagnocco A, Skellariou G, Talarico R, et al. Ultrasound imaging for the rheumatologist XLV. Ultrasound of the shoulder in psoriatic arthritis. Clin Exp Rheumatol. 2013;31:329–33.
43. Calin A, Garret S, Whitelock H, Kennedy LG, O'Hea J, Mallorie P, et al. A new approach to defining functional ability in ankylosing spondylitis: the development of the Bath Ankylosing Spondylitis Functional Index. J Rheumatol. 1994;21:2281–5.
44.• Ward MM. Complications of total hip arthroplasty in patients with ankylosing spondylitis. Arthritis Care Res. 2019;71:1101–8. https://doi.org/10.1002/acr.23582. **Complications after primary total hip artroplastia are uncommon in patients with AS and similar in frequency to those without AS**.
45. Lian F, Yang X, Liang L, Xu H, Zhan Z, Qiu Q, et al. Treatment efficacy of etanercept and MTX combination therapy for ankylosing spondylitis hip joint lesion in Chinese population. Rheumatol Int. 2012;32:1663–7. https://doi.org/10.1007/s00296-011-1844-8.
46. Konsta M, Sfikakis PP, Bournia VK, Karras D, Iliopoulos A. Absence of radiographic progression of hip arthritis during infliximab treatment for ankylosing spondylitis. Clin Rheumatol. 2013;32:1229–32. https://doi.org/10.1007/s10067-013-2263-x.
47.• Song R, Chung SW, Lee SH. Radiographic evidence of hip joint recovery in patients with ankylosing spondylitis after treatment with anti-tumor necrosis factor agents: a case series. J Rheumatol. 2017;44:1759–60. https://doi.org/10.3899/jrheum.161401. **An increase in hip joint space after anti-TNF-α treatment was observed in all patients with AS**.
48. Nystad TW, Furnes O, Havelin LI, Skredderstuen AK, Lie SA, Fevang BTS. Hip replacement surgery in patients with ankylosing spondylitis. Ann Rheum Dis. 2014;73:1194–7. https://doi.org/10.1136/annrheumdis-2013-203963.
49. Hidding A, van der Linden S, Boers M, Gielen X, de Witte L, Kester A, et al. Is group physical therapy superior to individualized therapy in ankylosing spondylitis? A randomized controlled trial. Arthritis Care Res. 1993;6:117–25. https://doi.org/10.1002/art.1790060303.
50. Lim HJ, Moon YI, Lee MS. Effects of home-based daily exercise therapy on joint mobility, daily activity, pain, and depression in patients with ankylosing spondylitis. Rheumatol Int. 2005;25:225–9. https://doi.org/10.1007/s00296-004-0536-z.
51. Hawley S, Sacks S, Bowness P, Prieto-Alhambra D. Incidence of total hip and knee replacement in UK patients with Ankylosing spondylitis. J Rheumatol. 2018;45:1334–6. https://doi.org/10.3899/jrheum.171387.
52. Ward MM, Deodhar A, Akl EA, Liu A, Ermann J, Gensler LS, et al. American College of Rheumatology/Spondylitis Association of America/Spondyloarthritis Research and Treatment Network 2015 Recommendations for the Treatment of Ankylosing Spondylitis and Nonradiographic Axial Spondyloarthritis. Arthritis Rheum. 2016;68:282–98. https://doi.org/10.1002/art.39298.
53.•• van der Heijde D, Ramiro S, Landewé R, Baraliakos X, Van den Bosch F, Sepriano A, et al. 2016 update of the ASAS-EULAR management recommendations for axial spondyloarthritis. Ann Rheum Dis. 2017;76:978–91. https://doi.org/10.1136/annrheumdis-2016-210770. **Collaborative document provides guidance on non-pharmacological and pharmacological management in patients with axial spondyloarthritis into one set applicable to the full spectrum of patients with axSpA**.