




Original research

No radiographic sacroiliitis progression was observed in patients with early spondyloarthritis at 6 years: results of the Esperanza multicentric prospective cohort

Cristina Fernández-Carballido ¹, Carolina Tornero ², M Carmen Castro-Villegas,³ Eva Galindez,⁴ José Francisco García-Llorente,⁵ María Luz García-Vivar,⁴ Beatriz Joven-Ibáñez,⁶ Xavier Juanola,⁷ Claudia Urrego-Laurín,⁸ Clementina López-Medina ⁹, Raquel Almodovar,¹⁰ Nieves Martínez-Alberola,¹¹ Teresa Ruiz-Jimeno,¹² Eugenio de Miguel² and ESPERANZA study group

To cite: Fernández-Carballido C, Tornero C, Castro-Villegas MC, *et al.* No radiographic sacroiliitis progression was observed in patients with early spondyloarthritis at 6 years: results of the Esperanza multicentric prospective cohort. *RMD Open* 2020;**6**:e001345. doi:10.1136/rmdopen-2020-001345

Received 28 May 2020

Revised 30 July 2020

Accepted 21 August 2020

ABSTRACT

Objective To estimate the 6-year radiographic progression of sacroiliitis in patients with early spondyloarthritis (SpA).

Patients and methods Sacroiliac joint (SIJ) radiographs (baseline and 6 years) of 94 patients with recent-onset SpA from the Esperanza cohort were scored, blindly and in a random order, by nine readers. The modified New York criteria were used to define the presence of sacroiliitis. As the gold standard for radiographic (r) sacroiliitis, the categorical opinion of at least five readers was used. Progression was defined as the shift from non-radiographic (nr) to r-sacroiliitis.

Results In the 94 SIJ radiographs (baseline and 6 years), 78/94 (83%) pairs of radiographs had not changed from baseline to 6 years. Sacroiliitis was present in 20 patients at baseline (21.3%) and in 18 (19.2%) patients at 6 years; 11 patients had sacroiliitis at both the baseline and final visits; 9 patients changed from baseline r-sacroiliitis to nr-sacroiliitis at 6 years, and 7 changed from baseline nr-sacroiliitis to r-sacroiliitis at 6 years. The mean continuous change score (range: -8 to +8) was 2.80 at baseline and 2.55 at 6 years (mean net progression of -0.25). The reliability of the readers was fair (mean inter-reader kappa of 0.375 (0.146–0.652) and mean agreement of 73.7% (58.7–90%)).

Conclusion In the early SpA Esperanza cohort, progression from nr-axSpA to r-axSpA over 6 years was not observed, although the SIJ radiographs scoring has limitations to detect low levels of radiographic progression.

INTRODUCTION

Radiographic assessment of the sacroiliac joints (SIJ) plays an important role in the diagnosis of patients with axial spondyloarthritis (axSpA) as well as in their classification.¹ Definite radiographic (r)

Key messages

What is already known about this subject?

- ▶ A recent review disclosed that approximately 10–40% of the patients with nr-axSpA progress to r-axSpA over a period of 2–10 years. However, some early cohorts have shown progression rates of about 5% at 5 years.

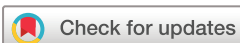What does this study add?

- ▶ In the early SpA Esperanza cohort, progression from nr-axSpA to r-axSpA over 6 years was not observed. We had a low net change of -0.25, which is below clinically relevant change and probably can be attributed to the measurement error.

How might this impact on clinical practice?

- ▶ Recent studies on early SpA cohorts show less radiographic progression than the reported in classical cohorts. If this is the case, an increase in the prevalence of nr-axSpA would be expected. To deepen the knowledge about the evolution of the patients with early SpA, we would ought to improve the assessment of SIJ damage and also ascertain whether early diagnosis delays radiographic progression.

sacroiliitis (at least a bilateral grade 2 or a unilateral grade 3 or 4) is a requirement for making the diagnosis of ankylosing spondylitis (AS) according to the modified New York (mNY) criteria² and is also a cornerstone in the image arm of the Assessment of SpondyloArthritis international Society (ASAS) axial classification criteria.¹ Thus, patients with axSpA are currently divided into two groups: those with r-axSpA or AS, with radiographic damage of the SIJ



© Author(s) (or their employer(s)) 2020. Re-use permitted under CC BY-NC. No commercial re-use. See rights and permissions. Published by BMJ.

For numbered affiliations see end of article.

Correspondence to

Cristina Fernández-Carballido; sofcarballido@hotmail.com

(fulfilling X-ray mNY criteria); and those with non-radiographic axSpA (nr-axSpA), defined by the absence of definite r-sacroiliitis. Conventional radiography of the SIJ is the first recommended imaging method when axSpA is suspected, according to the EULAR recommendations.³ However, the complex anatomy of the SIJ makes the interpretation of conventional radiographs challenging, and sacroiliitis recognition can be difficult. In this regard, several studies have consistently shown large inter-observer variability among trained readers^{4–6} and between central and local readers⁶ and no improvement after training.⁷ A proportion of patients with nr-axSpA might never develop definite radiographic damage, whereas others will experience a shift from nr-axSpA to r-axSpA.⁸ The celerity of this shift and its predisposing factors are still unclear,^{9,10} and data on recent-onset SpA cohorts are scarce. In this sense, our main objective was to evaluate the rate of SIJ radiographic progression in patients with recent-onset SpA (<2 years since onset of symptoms).

METHODS

We evaluated the SIJ radiographs of patients from the Esperanza Program, a Spanish prospective national health initiative intended to facilitate the early diagnosis and follow-up of patients with SpA. Details of this Program have been previously published.¹¹ In summary, patients eligible for inclusion were 18–45 years of age; had symptom duration between 3 and 24 months; and were experiencing inflammatory back pain, asymmetrical arthritis, or spinal or joint pain plus one SpA feature. The Program protocol was approved by the Research Ethics Committee of Hospital Reina Sofía, Córdoba, Spain. For the current study, 292 SIJ radiographs were used for the reliability study, of which 94 pairs (baseline and 6 years) were available for the radiographic progression study. All radiographs were scored by nine readers, blinded for time order and clinical data. All readers were experienced rheumatologists and members of the Spanish spondyloarthritis working group (GRESSER). All pairs (baseline and 6 years) of SIJ radiographs were evaluated as specified in the mNY criteria³ and graded accordingly (from 0 to 4). Thus, r-sacroiliitis was defined if at least a bilateral grade 2 or a unilateral grade 3 or 4 was present. The categorical opinion for positive r-sacroiliitis by at least five readers was considered the gold standard.

STATISTICS

We determined the proportion of ‘progressors’ (% of patients with worsening) as well as the proportion of ‘regressors’ (% of patients with improvement). Progression was defined as the shift from non-radiographic (nr)- to r-sacroiliitis and regression as the switch from r-sacroiliitis to nr-sacroiliitis at 6 years. In addition, ‘net’ percentage of progression was defined as the number of ‘progressors’ minus the number of ‘regressors’ divided

by the total number of the study population.¹² Also, the continuous change score was calculated (range: –8 to +8), where a negative value means the mNY grade at 6 years is lower than the grade at baseline.¹³ Inter-reader reliability was calculated by the Cohen’s kappa value and agreement among the readers.

RESULTS

Radiographic progression of the SIJ was evaluated at 6 years in 94 pairs of radiographs. The baseline characteristics of the 94 patients whose radiographs were scored were as follows: 50 patients (53.2%) were male; mean (SD) age was 34 (7.5) years (range: 18–45 years); HLA-B27 was positive in 39 patients (41.5%) and missing in 1 patient (1.06%); 27.9% of the patients were present smokers, 21.3% ex-smokers (stopped more than one year before the study) and 50.8% never smoked; mean (SD) levels of C reactive protein and erythrocyte sedimentation rate were 4.96 (6.54) mg/L and 11.31 (11.84) mm/hour, respectively.

Regarding the presence of r-sacroiliitis, at baseline, it was present in 20/94 (21.3%) patients, and at 6 years, it was present in 18/94 (19.2%) patients. In total, 78/94 (83%) pairs of radiographs had not changed from baseline to 6 years, with 11 (11.7%) pairs of radiographs showing sacroiliitis at both baseline and 6 years and 67 (71.3%) pairs of radiographs not showing sacroiliitis at baseline and 6 years. Regarding the changes in sacroiliitis status (binary), 16/94 (17%) pairs changed in 6 years, with 7 (7.5%) shifting from negative to positive at 6 years and 9 (9.6%) that were positive at baseline being negative at 6 years (net change of –0.02). The mean continuous change score (range: –8 to +8) was 2.80 at baseline and 2.55 at 6 years, with a mean net progression of –0.25.

The results of the reliability study in terms of the degree of agreement among the readers and kappa values are depicted in [table 1](#). The mean kappa achieved was fair at 0.375 (range: 0.146–0.652), and the mean agreement was 73.66% (range: 58.68– 89.93%). Larger discrepancies were observed when assessing grade 2 sacroiliitis.

DISCUSSION

Longitudinal studies about the change from non-radiographic axial spondyloarthritis (nr-axSpA) to radiographic axial spondyloarthritis (r-axSpA) have shown rates of 10–12% progression over 2 years^{5,14} and a recent review disclosed a progression rate of 10–40% over a period of 2–10 years.⁹ We have shown a small but negative ‘net’ progression that, given the early nature of the cohort (patients with a disease duration <2 years), would suggest no progression. The reported ‘net’ progression in the DESIR¹⁰ and ASAS¹⁵ cohorts was 5.1% at 5 years and 5% at 4.4 years of follow-up, respectively. At first glance, it would seem that recent studies are detecting less SIJ radiographic progression than the classical ones. However, the quantification of radiographic progression is susceptible to measurement error and, together with the

Table 1 Inter-reader reliability of the evaluation of SIJ radiographs in patients with early SpA from the Esperanza cohort

		R 2	R 3	R 4	R 5	R 6	R 7	R 8	R 9
R 1	Kappa	0.267	0.387	0.450	0.409	0.357	0.453	0.376	0.652
	Agreement	65.73	84.37	78.82	78.75	69.10	83.33	72.73	89.93
R 2	Kappa		0.146	0.330	0.326	0.318	0.244	0.338	0.250
	Agreement		58.68	67.01	66.66	65.97	63.19	66.66	63.54
R 3	Kappa			0.313	0.307	0.164	0.434	0.225	0.491
	Agreement			75.52	77.51	60.00	85.52	67.36	87.93
R 4	Kappa				0.405	0.416	0.420	0.415	0.507
	Agreement				75.09	71.38	75.59	72.92	81.38
R 5	Kappa					0.355	0.455	0.381	0.527
	Agreement					68.51	79.93	71.78	83.39
R 6	Kappa						0.300	0.417	0.348
	Agreement						66.21	71.18	68.62
R 7	Kappa							0.381	0.564
	Agreement							72.92	87.24
R 8	Kappa								0.382
	Agreement								73.26

The inter-reader kappa coefficients are shown in the upper part of the cells and the degree of agreement (in %) among readers is shown in the lower part of the cell, for each comparison between two of the readers. Mean kappa value was 0.375 (range: 0.146–0.652) and mean agreement was 73.66% (range: 58.7–90%).

R, reader; SIJ, sacroiliac joint; SpA, spondyloarthritis.

limited reliability of the SIJ radiograph scoring, might be the most likely reason for the absence of radiographic progression of the SIJ in our cohort, where the ‘regressors’ outweigh the ‘progressors’ and change over-and-above measurement error was not detected. Relatively high regression rates of r-sacroiliitis over time have been disclosed in other studies.^{5 9 15 16} For example, cross-tabulation of the results of the ASAS cohort revealed that more than half of the mNY-positive at baseline were mNY-negative at follow-up,¹⁵ pointing out that the interpretation of progression, regression and measurement error might not be easily unravelled. In this sense, some authors have proposed a new approach, the ‘assumption-free net progression’.¹³ Moreover, the limitations of the scoring of the SIJ radiographs in terms of reliability are known, especially in early stages of the disease.^{4–6 16–18} We disclosed a fair level of agreement between the readers (mean kappa value of 0.375) and a mean agreement of 73.7%, in line with a reported mean kappa value of 0.39 and agreement of 84.1% in 104 consecutive patients with low back pain ≥ 3 months of duration who met the ASAS definition for a positive SIJ magnetic resonance image or HLA-B27–positive arms.¹⁷ Regarding reliability, other studies have disclosed results from fair to moderate^{4–6} and no improvement after training.⁷ Furthermore, even central readers have only moderate agreement on the grade of sacroiliitis.¹⁸ Also, what is especially challenging is accurately detecting early or minimal abnormalities within the SI joint, particularly grades 1 and 2 on the mNY scoring scale,^{7 19} as it happened in our study.

Although we acknowledge that the limitations in the rating of the SIJ radiographs might have influenced the results, conventional radiography of the SIJ is still the first

recommended imaging method for suspicion of axSpA³ and to evaluate sacroiliitis progression.

Another question is whether the predominance of nr-axSpA (78.7% of the patients with paired radiographs available in our study) could also result in lower global rates of progression. Theoretically, this might be another possible explanation, but a study disclosed that patients with nr-axSpA showed even more progression (10.5%) than those with AS (4.4%).⁵ In addition, in a study of the same cohort, patients with nr-axSpA and AS not treated with tumour necrosis factor blockers demonstrated a similar clinical disease course over 2 years.²⁰

Last, another plausible explanation would be that early diagnosis and treatment may confer a ‘window of opportunity’ for patients with axSpA. Nonetheless, the design and results of our study prevent us from confirming this hypothesis.

In summary, in this group of patients with early SpA, no progression from nr-axSpA to r-axSpA over 6 years was observed. The limitations in the rating of the SIJ radiographs might impede the detection of low levels of radiographic progression, especially in early cohorts of axSpA.

Author affiliations

¹Rheumatology Department, Hospital Universitario San Juan de Alicante, Alicante, Spain

²Rheumatology Department, Hospital Universitario La Paz, Madrid, Spain

³Rheumatology Department, Hospital Universitario Reina Sofia/IMBIC, Cordoba, Spain

⁴Rheumatology Department, Hospital Universitario de Basurto, Bilbao, Spain

⁵Rheumatology Department, Hospital de Galdakao Usansolo, Bilbao, Spain

⁶Rheumatology Department, Hospital 12 de Octubre, Madrid, Spain

⁷Rheumatology Department, Hospital Universitari de Bellvitge/IDIBELL, Barcelona, Spain

⁸Rheumatology Department, Hospital Universitario Moncloa, Madrid, Spain

⁹Rheumatology Department, Hôpital Cochin, Paris, France

¹⁰Rheumatology Department, Hospital Universitario Fundación Alcorcón, Madrid, Spain

¹¹Rheumatology Department, Hospital Universitario de Elda, Elda, Spain

¹²Rheumatology Department, Hospital Universitario Marqués de Valdecilla, Santander, Spain

Acknowledgements The authors sincerely thank the staff members of Unidad de Investigación de la Fundación Española de Reumatología, who were involved in the Esperanza Program design and initial analyses, and all the local investigators of the Esperanza Program (see the Collaborators section) and all the patients of the study.

Collaborators ESPERANZA study group, E. Collantes, L. Carmona, M. Gobbo, J. Mulero, S. Muñoz-Fernández, P. Zarco, J. Rivera, J. C. López Robledillo, C. Castillo-Gallego, E de Miguel, J. Rosas, G. Santos, J. L. Fernández Sueiro, J.A. Pinto Tasende, E. González Díaz de Rábago, C. Montilla, S. Gómez Castro López, J. del Pino Montes, I. P. Granados Bautista, A. Hernández Sanz, J. Sanz Sanz, M. Fernández Prada, J. Tornero, C. Campos, J. Calvo, X. Juanola, V. Ríos, E. Moreno, M. I. Rotes, C. Fernández-Carballido, I. Ibero, V. Jovaní, N. Martínez-Alberola, L. F. Linares, M. J. Moreno Ramos, A. Uceda, M. J. Moreno Martínez, M. D. Beteta, J. C. Quevedo, C. Rodríguez Lozano, E. Trujillo, S. Bustabad, J. A. Román Ivorra, S. Muñoz Gil, A. Juan Mas, I. Ros Vilamajó, M. Ibañez Barceló, J. Gratacós, M. Moreno Martínez-Loza, R. Almodóvar, E. Rejón, S. Rodríguez Montero, T. Ruiz Jimeno, J. J. Aznar, E. Chamizo Carmona, N. Garrido Puñal, P. Fernández Dapica, E. Brito Brito, E. Pérez Pampín.

Contributors All authors were involved in the conception or design of the work, or the acquisition, analysis or interpretation of data, the drafting of the article or revising it critically for important intellectual content. The corresponding author attests that all listed authors meet authorship criteria and that no others meeting the criteria have been omitted. All authors have given final approval of the version to be submitted for publication and agree to be accountable for all aspects of the work in ensuring that questions related to the accuracy or integrity of any part of the work are appropriately investigated and resolved. EdM had full access to all of the data in the study and takes responsibility for the integrity of the data and the accuracy of the data analysis.

Funding The Spanish Foundation of Rheumatology received funding from Pfizer (formerly Wyeth) to develop the Esperanza Program and initial analyses. Later, the Program has been supported by restricted grants from the Instituto de Salud Carlos III and Fondos FEDER (FIS PI13/O2034 and PI17/O1840) and AbbVie.

Disclaimer The sponsors had no role in the study design; collection, analysis or interpretation of the data; the writing of the report; or in the decision to submit the article for publication.

Competing interests None declared.

Patient consent for publication Patients and/or the public were not involved in the design, or conduct, or reporting or dissemination plans of this research.

Ethics approval The programme was reviewed and approved by the Research Ethics Committee of Hospital Reina Sofía, Córdoba, Spain. The approval covers the analysis of the data described in this study.

Provenance and peer review Not commissioned; externally peer reviewed.

Data availability statement The data are shared and available to researchers in the spondyloarthritis working group (GRESSER) of the Spanish Society of Rheumatology and open to questions from researchers. Anonymised data are available upon reasonable request: clinical data, images, protocols and statistical analysis.

Open access This is an open access article distributed in accordance with the Creative Commons Attribution Non Commercial (CC BY-NC 4.0) license, which permits others to distribute, remix, adapt, build upon this work non-commercially, and license their derivative works on different terms, provided the original work is properly cited, appropriate credit is given, any changes made indicated, and the use is non-commercial. See: <http://creativecommons.org/licenses/by-nc/4.0/>.

ORCID iDs

Cristina Fernández-Carballido <http://orcid.org/0000-0002-0910-4944>

Carolina Tornero <http://orcid.org/0000-0001-8484-3475>

Clementina López-Medina <http://orcid.org/0000-0002-2309-5837>

REFERENCES

- Rudwaleit M, van der Heijde D, Landewé R, *et al.* The development of Assessment of SpondyloArthritis international Society classification criteria for axial spondyloarthritis (part II): validation and final selection. *Ann Rheum Dis* 2009;68:777–83.
- Van Der Linden S, Valkenburg HA, Cats A. Evaluation of diagnostic criteria for ankylosing spondylitis. *Arthritis Rheum* 1984;27:361–8.
- Mandl P, Navarro-Compan V, Terslev L, *et al.* EULAR recommendations for the use of imaging in the diagnosis and management of spondyloarthritis in clinical practice. *Ann Rheum Dis* 2015;74:1327–39.
- Yazici H, Turunç M, Ozdoğan H, *et al.* Observer variation in grading sacroiliac radiographs might be a cause of ‘sacroiliitis’ reported in certain disease states. *Ann Rheum Dis* 1987;46:139–45.
- Poddubnyy D, Rudwaleit M, Haibel H, *et al.* Rates and predictors of radiographic sacroiliitis progression over 2 years in patients with axial spondyloarthritis. *Ann Rheum Dis* 2011;70:1369–74.
- van den Berg R, Lenczner G, Feydy A, *et al.* Agreement between clinical practice and trained central reading in reading of sacroiliac joints on plain pelvic radiographs. Results from the DESIR cohort. *Arthritis Rheumatol* 2014;66:2403–11.
- Van Tubergen A, Heuft-Dorenbosch L, Schulpen G, *et al.* Radiographic assessment of sacroiliitis by radiologists and rheumatologists: does training improve quality? *Ann Rheum Dis* 2003;62:519–25.
- Poddubnyy D, Brandt H, Vahldiek J, *et al.* The frequency of non-radiographic axial spondyloarthritis in relation to symptom duration in patients referred because of chronic back pain: results from the Berlin early spondyloarthritis clinic. *Ann Rheum Dis* 2012;71:1998–2001.
- Protopopov M, Poddubnyy D. Radiographic progression in non-radiographic axial spondyloarthritis. *Expert Rev Clin Immunol* 2018;14:525–33.
- Dougados M, Sepriano A, Molto A, *et al.* Sacroiliac radiographic progression in recent onset axial spondyloarthritis: the 5 year data of the DESIR cohort. *Ann Rheum Dis* 2017;76:1823–8.
- Muñoz-Fernández S, Carmona L, Collantes E, *et al.* A model for the development and implementation of a national plan for the optimal management of early spondyloarthritis: the Esperanza Program. *Ann Rheum Dis* 2011;70:827–30.
- Landewe RBM, van der Heijde D. “Big data” in rheumatology: intelligent data modeling improves the quality of imaging data. *Rheum Dis Clin North Am* 2018;44:307–15.
- Sepriano A, Ramiro S, Landewé R, *et al.* Percentage of progressors in imaging: can we ignore regressors? *RMD Open* 2019;5:e000848.
- Sampaio-Barros PD, Conde RA, Donadi EA, *et al.* Undifferentiated spondyloarthropathies in Brazilians: importance of HLA-B27 and the B7-CREG alleles in characterization and disease progression. *J Rheumatol* 2003;30:2632–7.
- Sepriano A, Rudwaleit M, Sieper J, *et al.* Five-year follow-up of radiographic sacroiliitis: progression as well as improvement? *Ann Rheum Dis* 2016;75:1262–3.
- Poddubnyy D. Radiographic evaluation of sacroiliac joints in axial spondyloarthritis: still worth performing? *J Rheumatol* 2017;44:1–3.
- Christiansen AA, Hendricks O, Kuettel D, *et al.* Limited reliability of radiographic assessment of sacroiliac joints in patients with suspected early spondyloarthritis. *J Rheumatol* 2017;44:70–7.
- Rudwaleit M, Haibel H, Baraliakos X, *et al.* The early disease stage in axial spondyloarthritis: results from the German spondyloarthritis inception cohort. *Arthritis Rheum* 2009;60:717–27.
- Omar A, Sari I, Bedaiwi M, *et al.* Analysis of dedicated sacroiliac views to improve reliability of conventional pelvic radiographs. *Rheumatology (Oxford)* 2017;56:1740–5.
- Poddubnyy D, Haibel H, Braun J, *et al.* Clinical course over two years in patients with early nonradiographic axial spondyloarthritis and patients with ankylosing spondylitis not treated with tumor necrosis factor blockers: results from the German Spondyloarthritis Inception Cohort. *Arthritis Rheumatol* 2015;67:2369–75.